Human skeletal system

In that article I will try to bring closer the issue related to the general structure of the human skeletal system. I will also describe the methods of its presentation. I will also try to point out curiosities related to its structure and changes that occur in the skeleton starting from the birth of a person, through adolescence, adult life to old age. Moreover I will suggest directions for further analysis of the skeleton

1.General structure of the human skeletal system (skeleton).

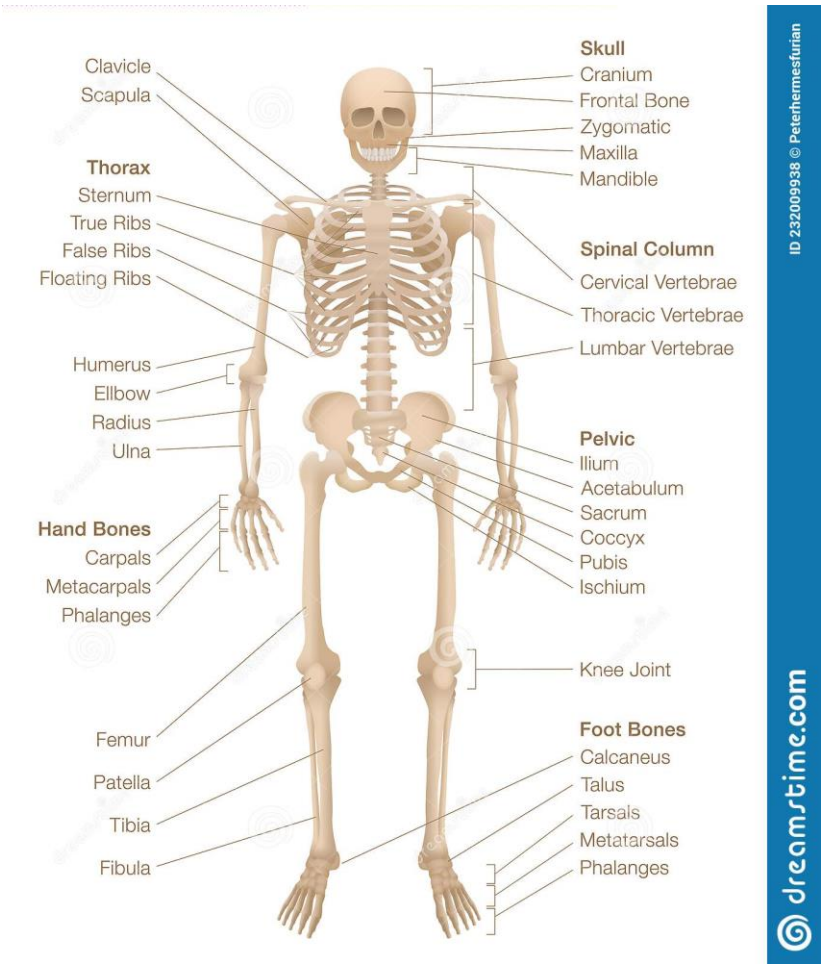

Fig. 1

The human skeleton, depicted in Fig. 1, can be divided into an axial skeleton and a skeleton of limbs.

The axial skeleton contains the spine, the bones of the head (including the skull) and the chest (torso). It is made of 80 bones. They compose 6 parts: the skull (22 bones), the auditory ossicles of the inner ear (2x 3 bones for each

side), the hyoid bone (1 bone), the chest (24 bones), the sternum (1 bone) and the spine (26 bones).

The skull is a bone or cartilaginous structure, which is the skeleton of the head. It is a natural cover of the brain and other organs located in the head. It consists of a canned brain-skull and a craniofacial (visceral). The upper part of the brain is the vault of the skull, and the lower part is the base of the skull.

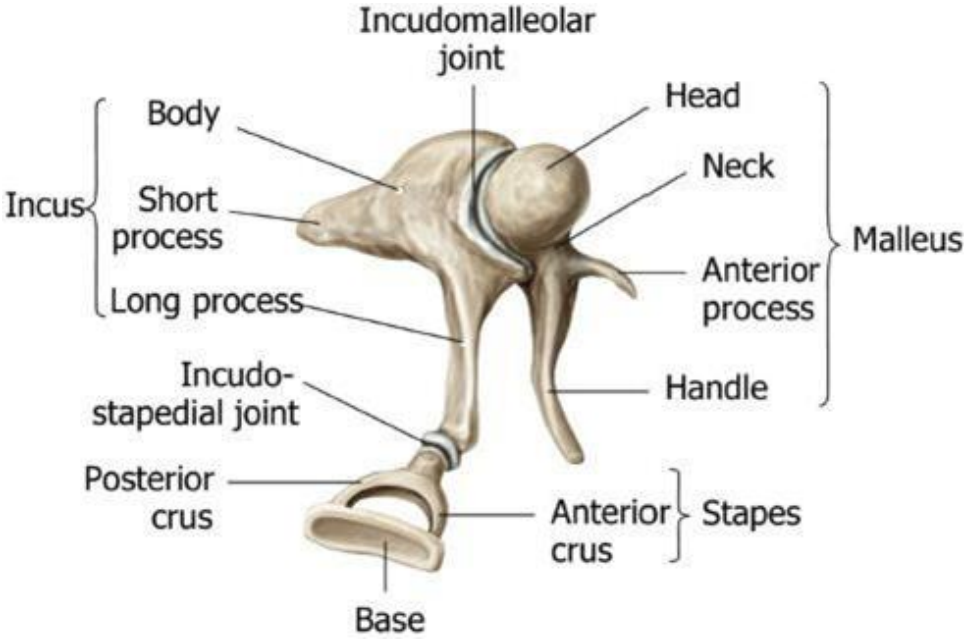

Fig. 2

In the head there are also auditory ossicles of 3 ossicles for each ear (Fig. 2). These are a malleus (hammer), an incus and a stapes. The malleus on one side connects to the tympanic membrane, and on the other to the incus. The incus, on the other hand, comes into contact with the stapes. And the stapes with the membrane of the oval window. The task of the auditory ossicles is to strengthen the vibrations of the tympanic membrane and bring the signal to the inner ear. These are the smallest bones in a human body.

The hyoid bone is an odd visceral bone that has no connection with other bones. It lies topographically within the neck, but despite that it is included in the bones of the skull. It has the shape of a horseshoe and is suspended below the mandible. It takes part in the movements of the larynx due to the connection with the disc cartilage by means of a ligament-ligamentous disc-hyoid membrane. It is necessary for the movement of the tongue and the swallowing.

The rib cage, shown in Fig. 3, protects the internal organs (mainly the heart and lungs) and enables the process of gas exchange. The skeleton of the chest consists of: a sternum, 12 pairs of ribs and 12 thoracic vertebrae.

Remark:

TRUE RIBS - RIBS NUMBERED I – VII, WHICH ARE CONNECTED DIRECTLY TO THE STERNUM, EACH WITH ITS OWN CARTILAGE,

PSEUDO RIBS – RIBS WITH NUMBERS VIII - X, CONNECTING TO THE STERNUM INDIRECTLY BY MEANS OF A COMMON CARTILAGE.

FREE RIBS – RIBS NUMBERED XI AND XII, HAVING NO CONNECTION TO THE STERNUM, HAVE FREE ENDS IN THE ABDOMINAL WALL.

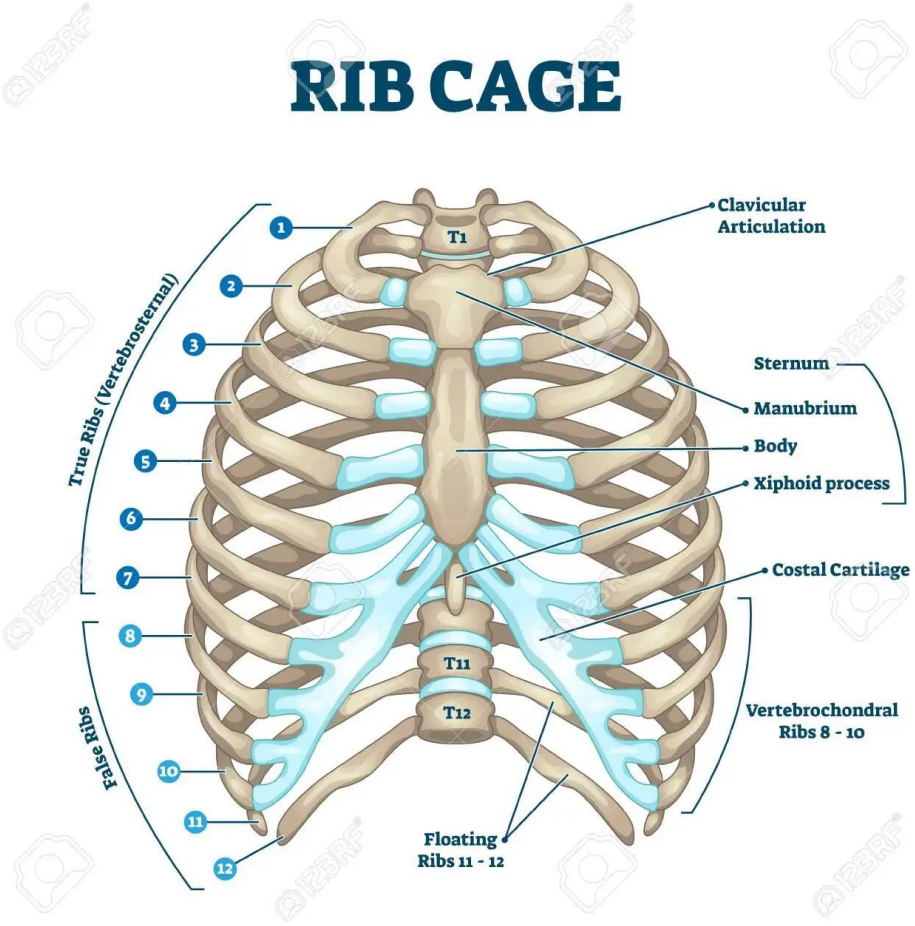

Fig. 3

The spine plays the role of a support organ, musculoskeletal system and a cover for the spinal cord. It consists of 26 bones, which include 24 separate vertebrae

and two bones formed from the fusion of the vertebrae: the sacrum and the tubercle bone.

Remark:

THE HUMAN SPINE (Fig. 4) IS DIVIDED INTO 5 SECTIONS, MARKED WITH DIFFERENT COLORS:

CERVICAL (7 CERVICAL VERTEBRAE, C1–C7, BROWN)

THORACIC (12 THORACIC VERTEBRAE, TH1–TH12, BLUE)

LUMBAR (5 LUMBAR VERTEBRAE, L1–L5, YELLOW)

SACRAL (5 FUSED SACRAL VERTEBRAE, OS SACRUM, GREEN)

NODULAR (4–5 FUSED NODULAR VERTEBRAE, COCCYX, PURPLE).

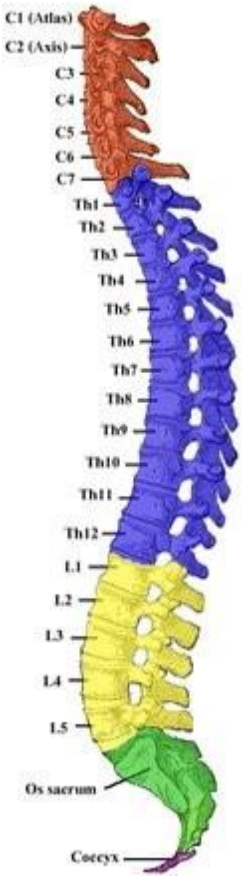

Fig. 4

The skeleton of the limbs, in fact, consists of two other skeletons: the upper and lower limbs.

The skeleton of the upper limbs contains the pectoral girdle and the bones of the upper limbs. In contrast, the skeleton of the lower limbs contains the pelvic girdle and the bones of the lower limbs. The skeleton of the limbs consists of 126 bones. The lower limbs perform transport functions (they move people), and the upper limbs are used to interact and manipulate objects.

Remark:

THE GIRDLE OF THE UPPER LIMB OF A MAN (PECTORAL GIRDLE) – A BONE STRUCTURE THAT IS PART OF THE SKELETON OF THE UPPER LIMBS. IT IS CONNECTED WITH THE HELP OF JOINTS. THIS IS THE POINT OF SUPPORT FOR THE MUSCLES OF THE UPPER LIMBS. THE UPPER LIMBS (RIGHT AND LEFT) ARE CONNECTED TO IT.

THE GIRDLE OF THE UPPER LIMB IS FORMED BY THE RIGHT AND LEFT ARMS. HOWEVER, EACH OF THE ARMS IS MADE OF A SHOULDER BLADE AND COLLARBONE.

IT CONSISTS OF THREE SECTIONS CONNECTED TO EACH OTHER BY JOINTS:

PROXIMAL CROSS-SECTION – ARM,

MIDDLE SECTION – FOREARM,

THE NEXT SECTION– HAND.

In human anatomy, the arm is the part of the limb that extends between the shoulder joint and the elbow joint. Anatomically, the shoulder girdle together with the corresponding muscles form the arm. The bony part of the arm is the humerus.

The forearm is the part of the upper limb, located between the hand and the shoulder (exactly between the wrist and the elbow joint). The bone part of the forearm is the radius and ulna. An important function of the mechanics of the forearm is supination and pronation, i.e. rotational movements of the forearm causing the rotation and reversal of the hand.

The hand is the terminal part of the upper limb. Used to interact with the environment. The bony part of the hand are the bones of the wrist, the bones of the metacarpus and the phalange.

The skeleton of the lower extremities contains the rim of the lower limb, also called the pelvic girdle. It is a set of bones forming a kind of ring connecting the free part of the lower limb (lower limb) with the axial skeleton.

The girdle of the lower limb consists of two pelvic bones, which, together with the sacrum and the nodule bone, form a stable bone ring, called the bone pelvis.

To sum up, the function of the pelvic girdle (shown in Fig. 5) is to connect the lower limbs to the spine (through the sacrum). The pelvis additionally has a protective function for the lower abdomen and internal pelvic organs such as the urinary tract canals and internal genitals.

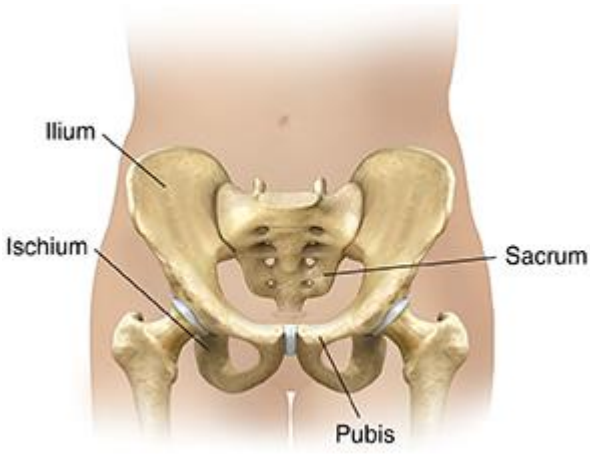

Fig. 5

In Fig. 5 you can also get acquainted with the connection of the pelvic bones (consisting of ilium, ischium and pubis) between each other and with the sacrum.

The lower limb, which beginning from the femur (Fig. 6) is the support organ of the human body and for locomotion, consists of:

Hips, thighs, kneecaps, lower legs (shins) and feet.

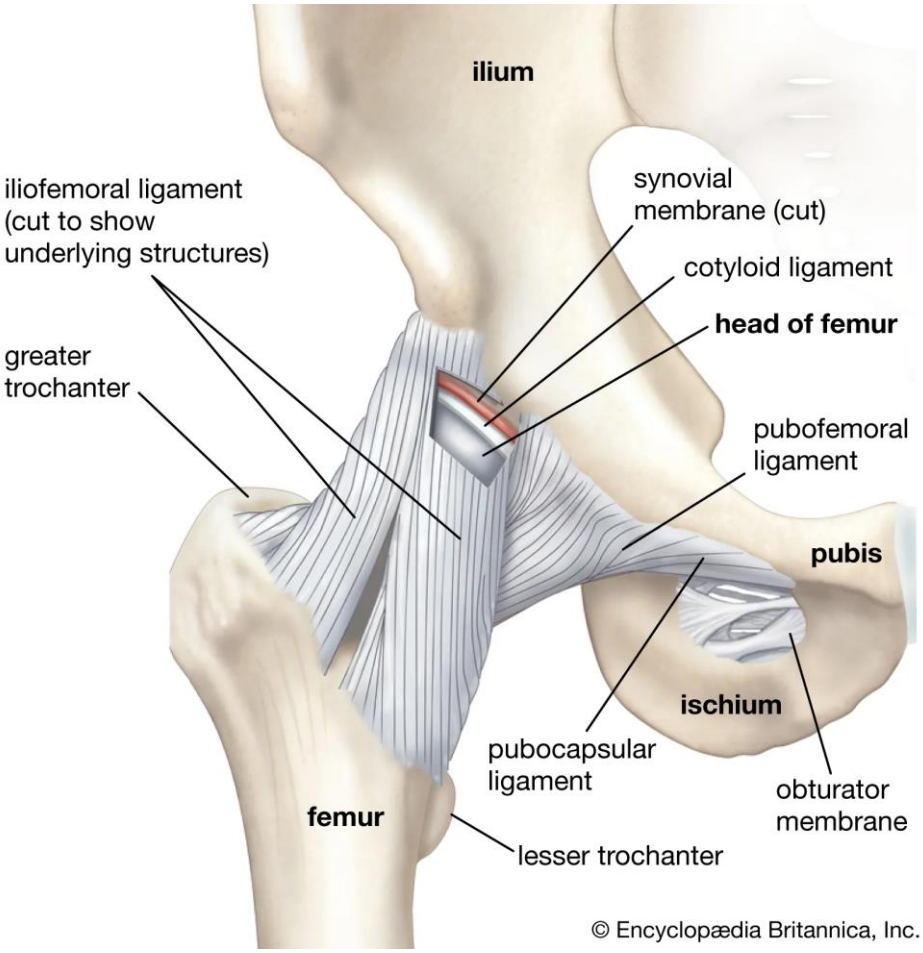

Fig. 6

The thigh is the part of the lower limb between the knee and hip joints.

The pelvic bone is an even bone that is part of the girdle of the lower limb. The pelvic bones connect with each other in the anterior part by means of a loonic symphysis, in the posterior part they connect to the sacrum. Two pelvic bones and the sacrum form the pelvis.

Each of the pelvic bones consists of the ilium, the sciatic ischium and the pubis . The iliac bone is very massive and durable.

The lower leg is an anatomical element of the lower limb land its skeleton is the tibia and the fibula.

In the tendon of the quadriceps muscle of the thigh is the patella. It is a bone flattened and slightly triangular. It is recognized that the patella is the largest hem* in the human body.

* Hems are ossified fragments of tendons that are supposed to protect them and improve their work, for example, by increasing the mechanical strength of the muscle.

2. Methods of presentation of the human skeletal system.

The most popular methods certainly include a multimedia presentation of the skeletal system, e.g. in Power Point. It may include photos of drawings depicting elements or the entire skeletal system, photos of a natural skeleton or anatomical models and plasticizers of natural human corpses. You can also present the skeletal system in the form of a traditional lecture and discuss it using the natural skeleton, selected fragments of it, and in the case of lack of such a skeleton or its poor condition, it can be replaced by an anatomical model. To support the teaching process, all kinds of textbooks with drawings and photos as well as boards are also used. Having consolidated knowledge on the above topic, it would be advisable - as medical students do - to get acquainted with natural corpses in the form of an autopsy.

3. Interesting facts related to the structure of the human skeleton and the changes taking place in it.

The human skeletal system is the internal structure of the human body. It is composed of about 270 bones at birth, with 356 in a 14-year-old. This number decreases in the following years, regardless of gender, to 206 bones, because part of the bones join together (e.g. skull bones). The proportion of bones in total body weight is approximately. 14% (approx. 10 kg for a woman and approx. 12 kg for a man). The proportion of minerals in bones is highest at the age of around 31.

Most of the unconnected bones are localized in the skull of the newborn the baby to be flexible enough to pass through the birth canal.

In the elderly, ossification occurs, i.e. bone fusion and their number drops below 206.

An interesting fact is certainly the formation of the patella by ossifying the tendon not as a degenerative change but as a change aimed at improving physical properties and thus improving the functioning of the knee joint. The combination of the patella with the tendon is also excellent.

In everyday language, the "anatomical" upper limb is often called the hand, while the term hand is corectly used to describe the palm.We distinguish the palm surface of the hand and the dorsal surface of the hand.

The foot is the final part of the lower limb that supports the weight of the body and allows you to move. It consists of 26 bones, 33 joints, 107 ligaments and 32 muscles - of which as many as 20 of them are responsible for maintaining proper posture. All this makes it one of the most complicated parts of the body. And the most overloaded.

In the course of evolution, as a result of obtaining by the man a vertical posture of the body, his mass was supported on the soles of the feet. As the result of that was the transformation of the skeleton and the muscles of the hind limb into the main support organ used for movement. Hind limbs became lower limbs.

4. Directions for further analysis of the skeleton.

As for further analysis of the skeleton, its external structure as well as its internal structure of individual bones can be analyzed. Their mineral structure such as density and physical strength can also be taken into account. It is also possible to deal with degenerative changes during the human life cycle (e.g. curvature, osteoporosis) as well as damage resulting from high-energy impacts. Such analysis will be most advisable for considering the methods of diagnosis, treatment and rehabilitation associated with the above-mentioned diseases and injuries.

Bartomiej Grząba